



Graham Simpson

# Investigation in chronic lung disease

*Too much, too little, just right!*

## Background

Lung problems are common in general practice. History and examination are invaluable; however considered selection of investigations can assist the clinician to reach a diagnosis.

## Objective

To outline the indications for common respiratory investigations to assist in selecting the most appropriate investigation for a clinical problem related to chronic lung disease.

## Discussion

The vast majority of problems related to chronic lung disease can be assessed with a full history and examination, a plain chest X-ray, a spirometer and a pulse oximeter. Chest X-ray should always be the initial radiological test. It can distinguish pneumonia from bronchitis and diagnose breathlessness caused by pneumonia, heart failure, pneumothorax, pleural effusion and interstitial lung disease. Computerised tomography scanning is not a useful test in investigation of symptoms such as breathlessness or cough when a chest X-ray is normal. Spirometry can be useful in the evaluation of chronic cough, wheezing, breathlessness or chest pain. Baseline oximetry should be performed on all dyspnoeic patients and those with abnormal spirometry.

**Keywords:** lung diseases; radiography, thoracic; spirometry; oximetry



Respiratory medicine is the most clinical of all the medical sub-specialties. Because of the structure of the respiratory tract and the different sound transmitting properties of air, consolidated lung and fluid, a great deal of information can be obtained from physical examination. The lungs are inflated with air, which provides a natural contrast medium for radiological investigation. Respiratory function can be accurately assessed with simple and inexpensive equipment easily used in the general practitioner's surgery.

The vast majority of problems related to chronic lung disease can be assessed with a full history and examination, a plain chest X-ray, a spirometer and a pulse oximeter. While there is a range of other investigations available, some are still being evaluated and some are highly specialised and more appropriate to specialist settings. This article will focus on those investigations most appropriate and accessible to general practitioners.

## Assessment of lung function

### Spirometry

Ideally all general practices should have a spirometer or, failing that, access to spirometry via a local hospital or respiratory physician. As well as providing values for forced expiratory volume in 1 second (FEV<sub>1</sub>) and forced vital capacity (FVC), electronic spirometers can print out a flow volume curve, which may provide additional information (Figure 1, 2). However, in routine use, measurement of FEV<sub>1</sub> and FVC provides most of the relevant clinical information.

### Indications for spirometry

- Evaluation of chronic cough, wheezing, breathlessness or chest pain
- Early detection of lung damage in the presence of known risk factors, especially smoking
- Monitoring all forms of chronic lung disease (eg. chronic obstructive pulmonary disease [COPD], asthma, bronchiectasis, interstitial lung disease)
- Objective assessment of disability
- Routine pre-operative assessment.



Figure 1. Electronic spirometer

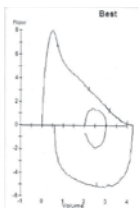
Contraindications to spirometry include:

- pneumothorax
- recent eye surgery
- recent thoracic or abdominal surgery
- haemoptysis of unknown origin
- unstable cardiovascular status such as recent myocardial infarction or arrhythmia
- known arterial aneurysm.

### Technique

Spirometry is simple but needs to be performed correctly.<sup>1</sup> Training is essential and it is better to refer than to perform the test poorly.

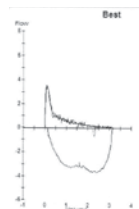
- The patient can be seated or standing; a nose clip is usually not required



	Result	Predicted normal	% predicted
FEV <sub>1</sub>	3.22 L	2.94 L	110
FVC	4.28 L	3.40 L	126
FEV <sub>1</sub> /FVC	75%	86%	

### Normal

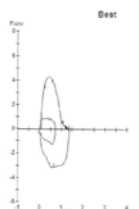
Normal expiratory flow volume curve with a triangular expiratory FEV curve. Flow rises rapidly from TLC up to peak flow and then descends fairly linearly to residual volume. (Note: normal range is generally taken as 80–120% of predicted, but values outside this do not necessarily indicate disease)



	Result	Predicted normal	% predicted
FEV <sub>1</sub>	1.06 L	2.73 L	39
FVC	3.14 L	3.53 L	89
FEV <sub>1</sub> /FVC	34%	77%	

### Obstructive

The flow rises to a much lower level of peak flow and then falls quickly with a very concave descending limb of the flow volume curve. This is typical of COPD. FEV<sub>1</sub>/FVC is reduced



	Result	Predicted normal	% predicted
FEV <sub>1</sub>	1.20 L	2.96 L	41
FVC	1.38 L	3.78 L	37
FEV <sub>1</sub> /FVC	87%	78%	

### Restrictive

Both FEV<sub>1</sub> and FVC are reduced and there is a high ratio between them of 87%. The flow volume curve rises and falls fairly symmetrically and forced expiratory time is reduced

- The doctor or practice nurse should demonstrate the technique using a spare mouthpiece
- The patient takes as big a breath as possible and then, sealing the lips around the spirometer mouthpiece, expires as hard and fast as possible and breathes out for as long as possible.

Ideally three manoeuvres to within 0.2 L for both FEV<sub>1</sub> and FVC should be obtained with the largest value for each parameter taken as the result. Some spirometers offer inspiratory flow volume loops, but in routine practice these are unimportant. Many also offer automatic interpretation of the results but these should not be relied on.

Common errors in spirometry include:

- incomplete inspiration to total lung capacity before the manoeuvre starts
- occlusion of the mouthpiece orifice by the lips or tongue
- variable effort
- premature cessation of expiration
- failure to seal the lips firmly around the mouthpiece
- failure to remain upright during the test.

### Interpretation of results

A normal expiratory flow volume curve is essentially a triangle with flow rising rapidly at the start of exhalation from total lung capacity to the peak flow value and then declining steadily in a fairly straight line until the flow ceases at residual volume.

In obstructive lung disease, FEV<sub>1</sub> is reduced but vital capacity is either normal or reduced to a lesser extent. The ratio between FEV<sub>1</sub> and FVC thus goes down. A ratio of less than 0.7 is taken as evidence of significant airflow limitation. In restrictive lung disease, both FEV<sub>1</sub> and FVC go down proportionately, so the ratio between them is

Figure 2. Spirometry patterns

normal or high. This is the pattern seen in interstitial lung diseases such as idiopathic pulmonary fibrosis, extrinsic allergic alveolitis, sarcoidosis, and asbestosis. The same pattern is also seen in chest wall disease such as kyphoscoliosis.

### Reversibility testing

Testing for reversibility of airflow obstruction by administration of a bronchodilator should be done at least once. Spirometry is performed before and 10–15 minutes after administration of a short acting beta agonist such as salbutamol 200 µg.

Reversibility is calculated as:

$$\frac{\text{Post-bronchodilator FEV}_1 - \text{pre-bronchodilator FEV}_1}{\text{Pre-bronchodilator FEV}_1} \times 100$$

Significant reversibility is an improvement in FEV<sub>1</sub> of 15% or more with an improvement of at least 200 mL. A rise of 400 mL or more is strongly indicative of asthma, however reversibility can be seen in other airways diseases such as COPD. Absence of bronchodilator reversibility does not exclude a diagnosis of asthma, as the patient may not be symptomatic at the time.

Unfortunately the Medicare item number for spirometry includes reversibility testing as part of the procedure. This provides a financial disincentive to spirometric monitoring of chronic lung diseases and a perverse incentive to perform unnecessary reversibility testing at every visit, which is not indicated in COPD or interstitial lung disease.

### Pulse oximetry

Pulse oximeters are inexpensive and readily available (Figure 3). Measuring arterial oxygen saturation (SpO<sub>2</sub>) can be useful to help distinguish asthma (where gas transfer and hence saturations are



Figure 3. Pulse oximeter

usually normal) from emphysema (where resting arterial oxygen saturation may be reduced to the low 90s or below). In COPD, measurements of SpO<sub>2</sub> can identify the point when arterial blood gas testing is indicated to assess for long term home oxygen therapy. This should usually occur when SpO<sub>2</sub> falls below 90%. Baseline oximetry should be performed on all dyspnoeic patients and those with abnormal spirometry.

### Imaging

#### Chest X-ray

A plain X-ray should always be requested before any other imaging of the chest is contemplated. It is a cheap and safe investigation (radiation dose 0.02 mSv, equivalent to 2–3 days of background cosmic radiation). A chest X-ray can distinguish pneumonia from bronchitis and diagnose breathlessness caused by pneumonia, heart failure, pneumothorax, pleural effusion and interstitial lung disease. Most primary lung tumours will be visible on plain radiography by the time they have caused symptoms.

Abnormalities on chest X-ray are best evaluated by comparison with an old chest X-ray. This allows evaluation of whether any lesions are new or old and whether they are changing. If old chest X-rays are not available, minor abnormalities can often be followed by serial radiography.

#### Computerised tomography

Computerised tomography (CT) scanning of the chest should rarely be ordered in general practice.<sup>2</sup> Most requests fail to solve the GP's clinical problem.<sup>3</sup> Computerised tomography is an expensive test and exposes the patient to high levels of radiation (about 8 mSv, equivalent to about 400 chest X-rays).<sup>4</sup> The dose to the breast may be as high as 33 mSv.<sup>5</sup> Best estimates are that this dose of radiation causes a fatal cancer in one in 2500 people exposed overall, with much higher risks in younger patients.<sup>6</sup> It is estimated that in the United States of America, 2% of all cancers are now caused by radiation exposure from CT scanning.<sup>7</sup>

#### Conventional CT with contrast

This is the usual CT scan and provides images of the chest wall, mediastinum and pleura, as well as lung windows. As a staging investigation for lung cancer the scan is extended to include the upper abdomen, specifically the liver and adrenal glands. However, if the suspected lung cancer or pleural effusion is visible on chest X-ray, the patient needs referral for histological diagnosis and this should take priority over a CT scan.

#### High resolution CT

A high resolution CT (HRCT) scan is not simply a better CT scan. The technique is different. It is a noncontrast examination where lung windows are scanned. A 1 mm slice is taken,



usually every centimetre, so that only about 10% of the lung volume is actually sampled; small lesions may be missed completely. It is designed to examine fine detail of the anatomy of the lung and is used in the assessment of interstitial lung diseases and in the diagnosis of bronchiectasis.

Computerised tomography scanning is not a useful test in investigation of symptoms such as breathlessness or cough when chest X-ray is normal.

In COPD, imaging is generally not very useful. Severe COPD can be present with a normal chest X-ray, or HRCT, and normal chest radiographs are often reported as suggestive of COPD because of hyperinflation when a healthy patient has simply taken a very good inspiration. The appropriate monitoring of the progression of COPD is with serial spirometry and, in the later stages, with pulse oximetry and not with imaging.

### Fibreoptic bronchoscopy

Referral to a specialist for fibreoptic bronchoscopy should be the first course of action in the following situations:

- suspected foreign body inhalation
- chest X-ray showing a mass
- pulmonary, lobar or segmental collapse on chest X-ray
- haemoptysis
- recurrent pneumonia in the same area.

Requests for further imaging in these situations are simply likely to delay diagnosis and may be misleading. With the advent of endo-bronchial ultrasound techniques, fibreoptic bronchoscopy is becoming the modality of choice for mediastinal lymph node sampling and lung cancer staging and is replacing CT guided fine needle aspiration for peripheral lung masses.<sup>8</sup> In addition it has therapeutic potential in the removal of foreign bodies, mucus plugs and in controlling life threatening haemoptysis by balloon tamponade.

### Principles in practice

Eponymous names can be a way to aid recall. In that spirit, the following principles and case studies may help when considering investigations.

#### Simpson's first law

The best test in respiratory medicine is an old chest X-ray.

#### Simpson's second law

With regard to medical investigations: 'If your next course of action will be the same whatever the result of the proposed investigation, then don't do the test'.

#### William of Ockham 1288–1348

English philosopher now best known for 'Ockham's razor': '*Plurilatus non est ponenda sine necessitate*'. Loosely translated and paraphrased to be applied to medicine, Ockham's razor states that: if there are a number of possible explanations for a phenomenon the simplest is most likely to be correct.

### Willie Sutton 1901–1980

American Bank Robber

Famous for reportedly replying to a journalist who asked him: "Why do you keep robbing banks?" by saying "Because that's where the money is."

Sutton's law, as applied to medicine, states that investigations should be directed to the site of the pathology and the best initial investigation is the one which is likely to give the most diagnostic information. For example, in investigation of a pleural effusion, examination of the pleural fluid or medical thoracoscopy is preferred to any form of imaging because the 'money' is in the pathology in the pleural space.

### Case study 1 (Simpson's first law)

A woman, 61 years of age, had three CT scans of the chest in 5 years by different practitioners to investigate a small opacity obscuring the lower end of the left heart border. When asked to do so, she managed to find an X-ray dating from 20 years ago which showed identical appearances. All the CT scans showed that the shadowing was an old fibrotic scar; simply looking at the first X-ray would have been enough to know that the lesion was old and stable and did not require further investigation.

### Case study 2 (Simpson's second law)

An 86 year old ex-Lancaster bomber pilot from World War II with known severe COPD (FEV<sub>1</sub> 30% of predicted) presented with an incidental finding of a peripheral lung mass. This had not been present on X-ray 2 years earlier; he had a history of lifelong heavy smoking. He had been advised by an oncologist friend to have a CT scan and biopsy of this lesion. However, as no curative treatment of the lesion was possible, and it was not causing any symptoms, the patient and specialist agreed that making a definitive diagnosis would have no immediate impact on his subsequent treatment so no further investigations were performed. The patient eventually died 3 years later of an exacerbation of his COPD without the peripheral mass (which had enlarged and was undoubtedly a primary lung cancer) having caused any problems.

### Case study 3 (Ockham's razor)

A smoker, 60 years of age, presented with hoarseness and was found to have a serum sodium level of 122 mmol/L. A chest X-ray showed a hilar mass (*Figure 4*).

Numerous investigations were ordered to investigate the hyponatraemia, including urinary sodium level, thyroid function tests, midnight and 8 am serum cortisol levels and a Synacthen test.

On examination a hard right scalene node was palpable and a clinically guided needle aspiration with bedside cytology confirmed the diagnosis of small cell lung cancer with SIADH. The other tests were cancelled.

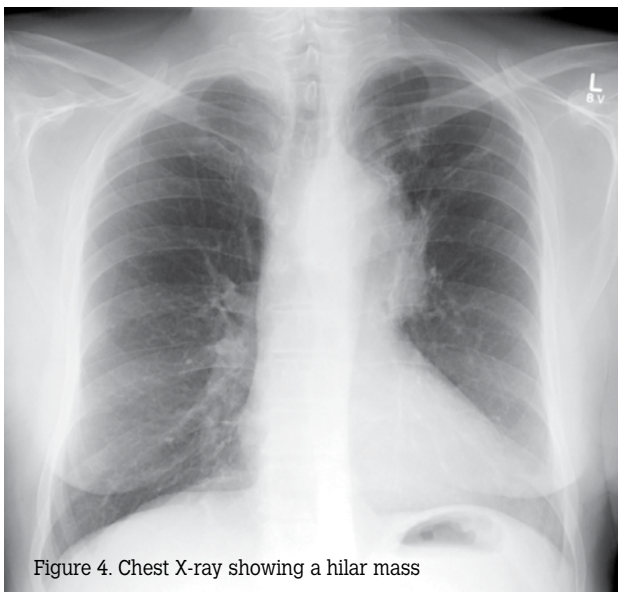


Figure 4. Chest X-ray showing a hilar mass

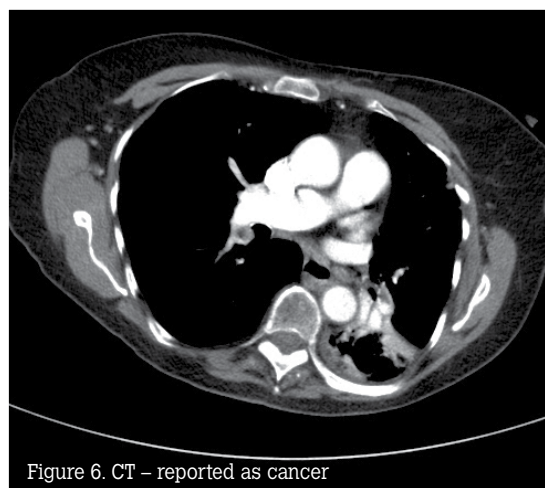


Figure 6. CT – reported as cancer

### Case study 4 (Sutton’s law)

A previously well woman, 70 years of age and a nonsmoker, had a persistently abnormal chest X-ray after treatment of a presumed pneumonia. The X-ray shows a classic left lower lobe collapse (Figure 5). Instead of applying Sutton’s law, the treating physicians ordered a CT scan which was reported as showing an obstructive lesion of the left lower lobe bronchus, probably malignant (Figure 6). The patient was told she had lung cancer and was extremely distressed. She was then referred for bronchoscopy when a large mucus plug was removed from the lower lobe bronchus resulting in complete re-expansion of the lung (Figure 7). She was discharged from hospital the following day. There was no cancer.

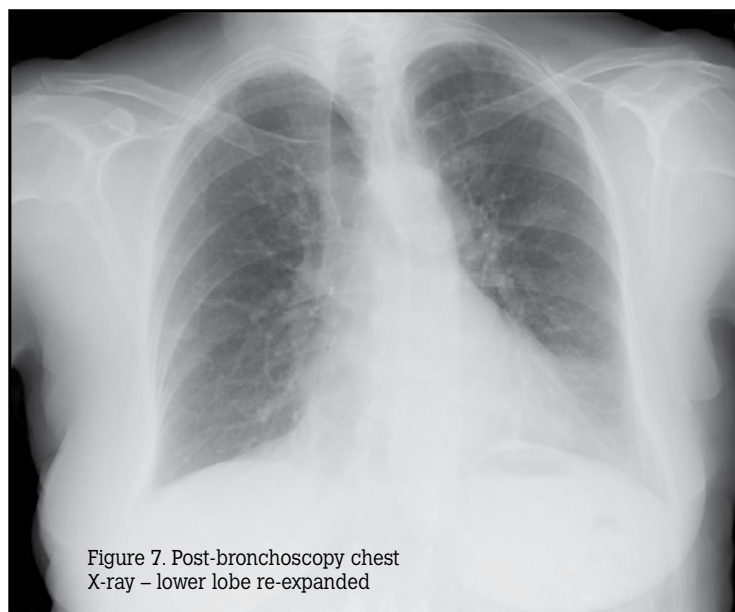


Figure 7. Post-bronchoscopy chest X-ray – lower lobe re-expanded

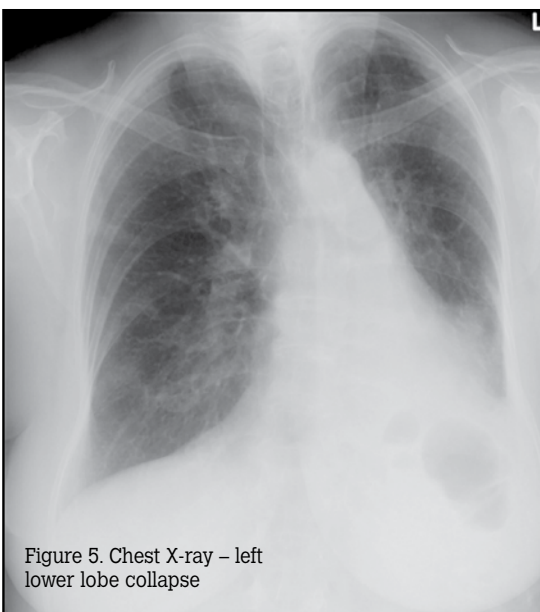


Figure 5. Chest X-ray – left lower lobe collapse

### Summary of important points

- History and physical examination are key to any assessment.
- Spirometry is a simple test but it must be done correctly to be useful. It can provide information on lung function to aid diagnosis or monitoring of lung conditions.
- Pulse oximetry is useful in diagnosis and management, particularly in COPD and asthma.
- Chest X-ray should always be the initial radiological examination.
- Referral for bronchoscopy is, at times, the first course of action.

### Author

Graham Simpson BSc, MD, FRACP, is Director of Thoracic Medicine, Cairns Base Hospital, and Adjunct Associate Professor, James Cook University Medical School, Queensland. fgsimpson@iig.com.au.



Conflict of interest: none declared.

## References

1. Miller MR, Hankinson J, Brusasco V, et al. Standardisation of spirometry. *Eur Respir J* 2005;26:319–38.
2. Simpson G. Thoracic computed tomography – principles and practice. *Australian Prescriber* 2009;32:105–7.
3. Simpson G, Hartrick GS. Use of thoracic computed tomography by general practitioners. *Med J Aust* 2007;187:43–6.
4. Rehani MM, Barry M. Radiation doses in computed tomography. *BMJ* 2000;320:593–4.
5. McCollough CH, Liu HH. Breast dose during electron beam tomography: measurement with film dosimetry. *Radiology* 2005;196:153–7.
6. Bremner D, Elliston C, Hull E, Bardon W. Estimated risks of radiation induced fatal cancer from paediatric CT. *Am J Roengenol* 2001;176:289–6.
7. Bremner DJ, Hall EJ. Computed tomography – an increasing source of radiation exposure. *N Engl J Med* 2007;357:2277–84.
8. Fielding DIK, Robinson PJ, Kurimoto N. Biopsy site selection for endobronchial ultrasound guide – sheath transbronchial biopsy of peripheral lung lesions. *Int Med J* 2008;38:77–84.

correspondence [afp@racgp.org.au](mailto:afp@racgp.org.au)